





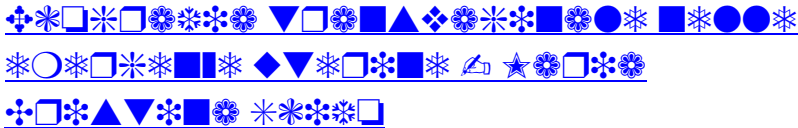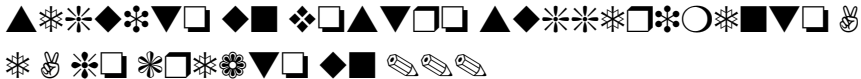
Access Free L Ecografia E Il Color Doppler In Nefrologia Tumori Del





Access Free L Ecografia E Il Color Doppler In Nefrologia Tumori Del




Access Free L Ecografia E Il Color Doppler In Nefrologia Tumori Del




Access Free L Ecografia E Il Color Doppler In Nefrologia Tumori Del





Access Free L Ecografia E Il Color Doppler In Nefrologia Tumori Del




Access Free L Ecografia E Il Color Doppler In Nefrologia Tumori Del




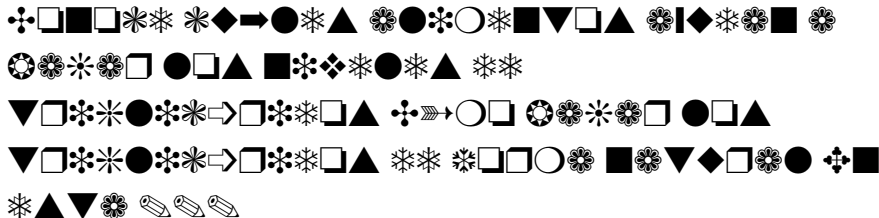
Access Free L Ecografia E Il Color Doppler In Nefrologia Tumori Del




Access Free L Ecografia E Il Color Doppler In Nefrologia Tumori Del




Access Free L Ecografia E Il Color Doppler In Nefrologia Tumori Del



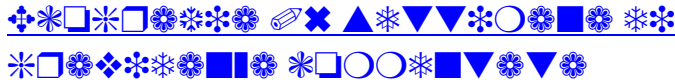
Access Free L Ecografia E Il Color Doppler In Nefrologia Tumori Del





Access Free L Ecografia E Il Color Doppler In Nefrologia Tumori Del




Access Free L Ecografia E Il Color Doppler In Nefrologia Tumori Del




Access Free L Ecografia E Il Color Doppler In Nefrologia Tumori Del




Access Free L Ecografia E Il Color Doppler In Nefrologia Tumori Del



Access Free L Ecografia E Il Color Doppler In Nefrologia Tumori Del



Access Free L Ecografia E Il Color Doppler In Nefrologia Tumori Del



Access Free L Ecografia E Il Color Doppler In Nefrologia Tumori Del